

## Renal angiomyolipomata

JOHN J. BISSLER and J. CHRIS KINGSWOOD

*Division of Nephrology and Hypertension, Cincinnati Children's Hospital Medical Center, Cincinnati, Ohio; and Sussex Renal Unit, The Royal Sussex County Hospital, Brighton, England*

**Renal angiomyolipomata.** Renal angiomyolipomata can exist as an imaging curiosity or represent a life-threatening condition. There are likely over 10 million people world-wide who have a renal angiomyolipomata and approximately one tenth of these people also have tuberous sclerosis complex. The optimum treatment of angiomyolipomata is focused on sparing renal tissue and has included no intervention, both total and partial nephrectomy, and embolization. As basic science investigation into the biology of angiomyolipomata progresses, there is even hope for successful drug therapy. Because these renal lesions can be associated with other organ system dysfunction, a number of medical specialists become involved in the care of affected patients. The purpose of this article is to update the nephrologist on the molecular understanding of renal angiomyolipomata and for the possibilities of pharmacologic therapy in the future.

Renal angiomyolipomata exhibit an extremely broad disease spectrum, from merely an imaging curiosity to a life-threatening condition. Using the estimated world population of over six billion individuals [1], the gender distribution and frequency of angiomyolipomata [2], there are over 10 million people world-wide with renal angiomyolipomata and approximately one tenth of these also have tuberous sclerosis complex. The optimum treatment of angiomyolipomata has logically focused on sparing renal tissue. It has included no intervention, both total and partial nephrectomy, and embolization. As basic science investigation into the biology of angiomyolipomata progresses, there is even hope for successful drug therapy, at least in tuberous sclerosis complex and lymphangiomyomatosis. Because these renal lesions can be associated with other organ system dysfunction, a number of medical specialists become involved in the care of affected patients. The purpose of this article is to update the nephrologist on the clinical and pathologic features of

this lesion, with special emphasis on the molecular understanding of renal angiomyolipomata in tuberous sclerosis and lymphangiomyomatosis. Recent basic science discoveries in these diseases offer hope for pharmacologic therapy in the future.

### DISEASE FREQUENCY AND ASSOCIATED CONDITIONS

Grawitz [3], in 1900, first used the term renal angiomyolipoma to describe a large renal tumor comprised of fat, muscle, and blood vessels. In a study of 8501 autopsies in which there were no stigmata of tuberous sclerosis complex recognized, Hajdu and Foote [4] found two males and 25 females with angiomyolipomata, resulting in frequencies of 0.02% and 0.29% of the total population, respectively. These data compare favorably to the imaging studies by Fujii et al [2] involving 12,970 male and 4971 female Japanese that identified angiomyolipomata in 13 (0.1%) males and 11 (0.22%) females. The difference in frequency in males in these two studies likely reflects the small numbers of males in each. The consistent increased frequency in females may be due in part to hormonal differences. Angiomyolipomata often express receptors for both estrogen and progesterone [5].

### ASSOCIATED CONDITIONS

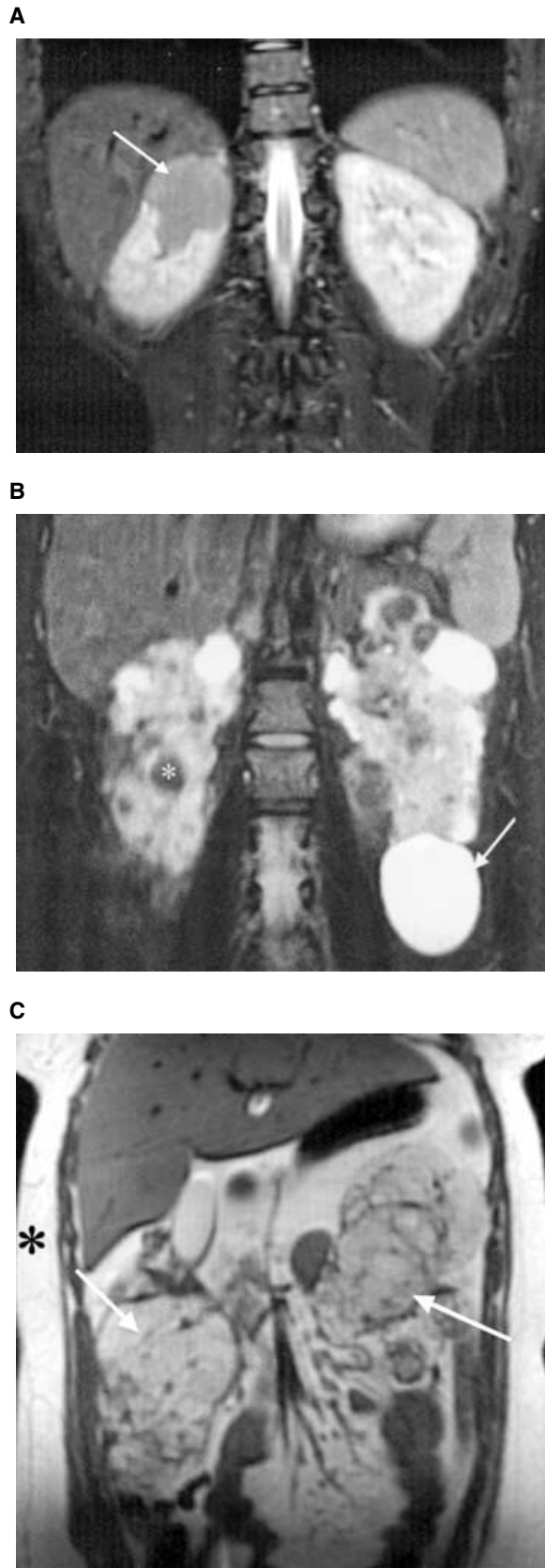
Although often found incidentally, renal angiomyolipomata can be associated with two conditions affecting other organ systems: tuberous sclerosis complex (TSC) and sporadic lymphangiomyomatosis (LAM). This review focuses on the angiomyolipomata in these diseases. Twenty years after Bourneville [6] described TSC, he and Brissaud [7] noted renal angiomyolipoma in patients with TSC. TSC actually has three renal phenotypes, including angiomyolipomata, cysts, and carcinoma. These lesions may occur individually or coexist (Fig. 1). Growth of angiomyolipomata in patients with TSC is often first detected during childhood [8] and continues into adulthood [9, 10]. An autopsy study found that 67% of TSC patients have angiomyolipomata [11]. The frequency of

---

**Key words:** angiomyolipomata, tuberous sclerosis complex, lymphangiomyomatosis, oncocytoma, epithelioid, PEComa.

Received for publication February 28, 2003  
and in revised form October 11, 2003, and November 11, 2003  
Accepted for publication February 10, 2004

© 2004 by the International Society of Nephrology

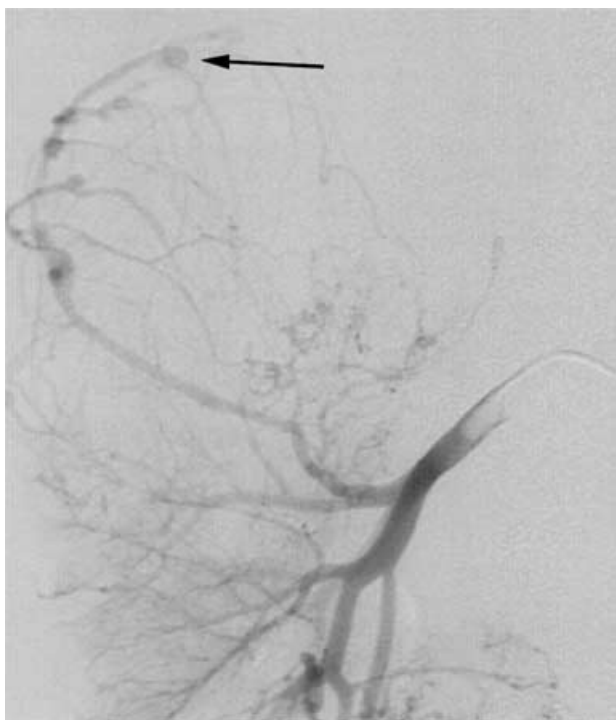


angiomyolipoma varies with the age of the population being studied; the frequency is higher in older subjects.

There are two morbidities associated with renal angiomyolipomata. The first and more dramatic is Wunderlich syndrome [12], retroperitoneal hemorrhage originating in the angiomyolipoma. Angiomyolipomata, as they enlarge, frequently develop both micro- and macroaneurysms which can rupture [13, 14]. Patients with this sudden, painful, and often life-threatening event are most often first seen in the emergency department. Up to 20% of patients with such hemorrhages present in shock [15]. With such a presentation, the treatment may be a total nephrectomy. This approach complicates the patient's long-term care. Angiomyolipomata associated with TSC are bilateral and a nephrectomy would result in a significant loss of functional renal tissue, thus hastening the need for renal replacement therapy. The risk of hemorrhage from renal angiomyolipomata has been reported to be between 25% and 50% [16]. A population study suggests that the cumulative risk of a hemorrhage is 18% for females and 8% for males [17]. However, among a clinic population of approximately 310 adult and pediatric tuberous sclerosis complex patients in Cincinnati, we have seen only nine cases of hemorrhage (~3%). This difference may be, at least in part, due to our aggressive embolization program, population age differences or length of follow-up. Although angiomyolipomata appear to grow over time, and there is an association between lesion size and hemorrhage [10, 18], bleeding is in fact much more strongly associated with aneurysm formation [19]. This, in part, explains why modest lesions and young patients can still have substantial hemorrhages. The likely scenario is that the larger aneurysms rupture and decompress into the retroperitoneal space or renal pelvis (Fig. 2).

The second morbidity of renal angiomyolipomata is the insidious encroachment of the angiomyolipoma on normal renal tissue, which may lead to renal failure [20, 21]. The precise incidence of end-stage renal disease (ESRD) in the tuberous sclerosis population has not been well defined, but European surveys suggest that approximately 1% of the TSC patient population with normal intellect is receiving dialytic renal replacement therapy [20, 21], leading to an estimate that over 30,000 TSC patients are

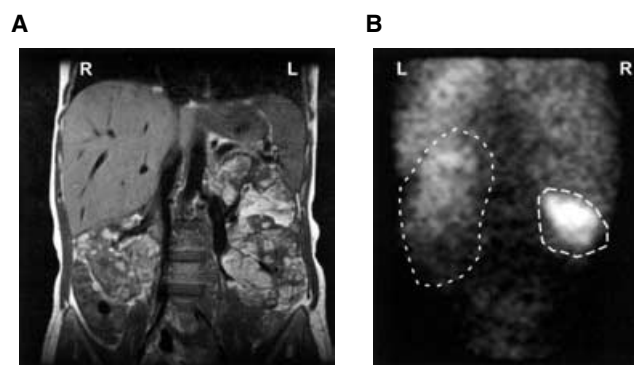
**Fig. 1. Magnetic resonance (MR) imaging of the renal lesions of three adult tuberous sclerosis complex (TSC) patients.** (A) Fast spin echo inversion recovery image demonstrates the lesion in the upper pole of the right kidney by the contrast with the normal kidney. (B) Fast spin echo T2-weighted image demonstrating the bright signal intensity of lesions compatible with a cyst (see arrow) and dark signal intensity lesion compatible with fat (asterisk). Both cystic and angiomyolipomata can be identified in both kidneys. (C) T1-weighted image with two lesions with increased signal intensity (arrows) similar to subcutaneous fat (asterisk), compatible with large angiomyolipoma.



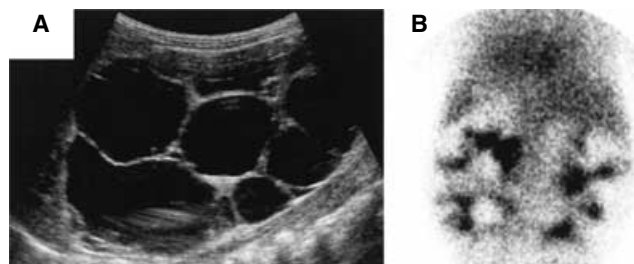
**Fig. 2. Angiography of the right kidney revealing angiomyolipoma of the upper pole with aneurysms.** The largest is marked with the arrow.

on dialysis worldwide. Shepherd et al [22] examined death certificates for patients in their TSC clinic and found that of 355 patients, 40 died as a result of their TSC, most commonly due to renal failure. These studies are helpful to understand the scope of disease, though the actual number of patients with renal insufficiency and comorbidities is unknown. The percentage of TSC patients developing ESRD because of polycystic kidney disease, multiple interventions for hemorrhage, or replacement of renal tissue by angiomyolipomata is unclear. Renal function is often normal even in patients with apparently bilateral confluent angiomyolipomata. Kidneys with a large angiomyolipoma burden can still contribute significantly to total renal function and the decision to undergo a nephrectomy should be carefully balanced against the loss of function (Fig. 3).

Approximately 35% of patients with TSC will have renal cysts [23]. Although these lesions may be large, they usually are not numerous and rarely cause problems. One exception is the polycystic kidney disease phenotype, or disease manifestation, of TSC, in which patients are at risk for the same morbidities as patients with autosomal polycystic kidney disease (Fig. 4). This phenotype is due to joint disruption of the *TSC2* gene and the very closely adjacent *PKD1* gene resulting in both TSC and polycystic kidney disease [24, 25]. Even patients with the polycystic phenotype can develop angiomyolipomata.



**Fig. 3. Demonstration of preserved function despite large angiomyolipoma burden in an adult.** (A) Magnetic resonance imaging (MRI) scan demonstrating significant involvement in the both kidneys. (B) Despite a large angiomyolipoma burden, the  $^{99m}\text{Tc}$ -diethylene-triamine pentaacetic acid ( $^{99m}\text{Tc}$ -DTPA) scan demonstrates function in both kidneys. The glomerular filtration rate for this patient was approximately  $95 \text{ mL/min/1.73 m}^2$ , and the right kidney contributed 44% of the total function. The functional kidney tissue is circled using a dotted line.

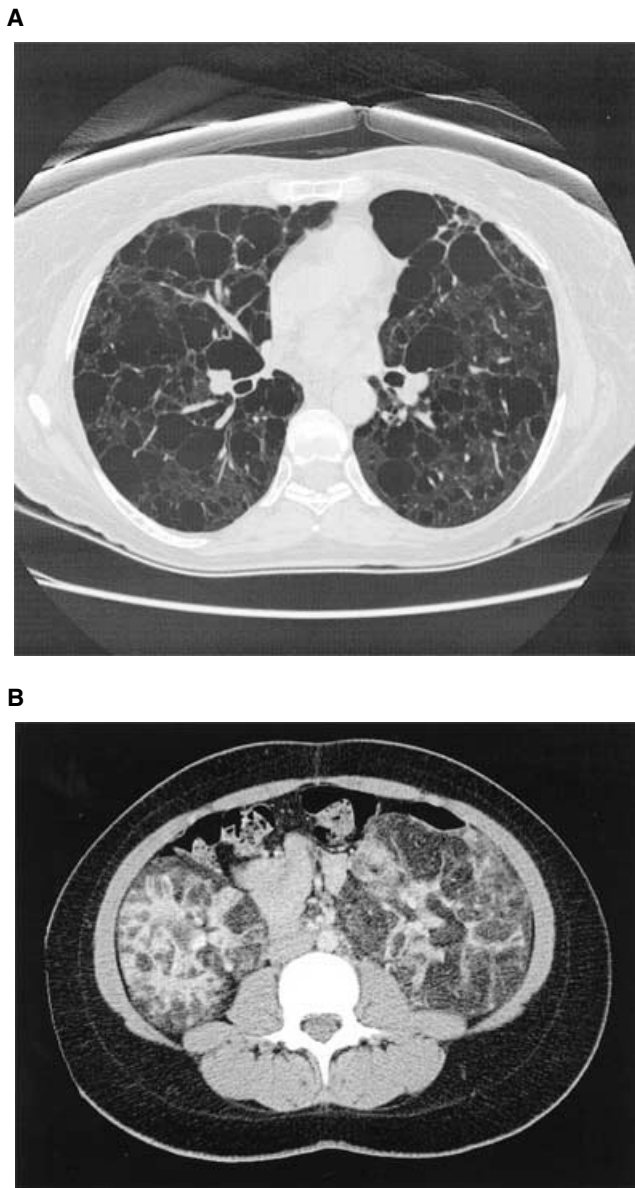


**Fig. 4. Polycystic renal variety of tuberous sclerosis complex (TSC) in a child.** (A) Renal ultrasound revealing significant polycystic disease. (B) Renal scan revealing functional renal tissue between the cysts. The child had a normal glomerular filtration rate and well-controlled hypertension.

Angiomyolipomata are also associated with LAM (Fig. 5), a disease involving the pulmonary interstitium which occurs almost exclusively in young females [26], though its presence in a male has been reported [27]. Approximately 40% of female patients with TSC also develop a cystic pulmonary disease consistent with LAM [28–30]. However, the disease progression may be different from the sporadic form of the disease and only approximately 1% of women with TSC develop clinical symptoms [31].

LAM also occurs in patients without TSC (denoted as sporadic LAM). This sporadic form is rare, less than 1000 affected women have been identified world-wide [32], and 60% of these patients also have an angiomyolipoma [11]. The angiomyolipoma histopathologic features seen in sporadic LAM are identical with those found in TSC [33].

Both TSC associated and sporadic LAM is characterized by smooth muscle infiltration into the walls of the alveoli and small airways. This can lead to cystic



**Fig. 5. Utility of computed tomography (CT) in lymphangiomyomatosis (LAM).** (A) High resolution CT scan revealing cystic parenchymal changes of LAM. (B) Renal CT scan demonstrating multiple lesions of  $-15$  to  $-100$  Hounsfield units, characteristic of fat.

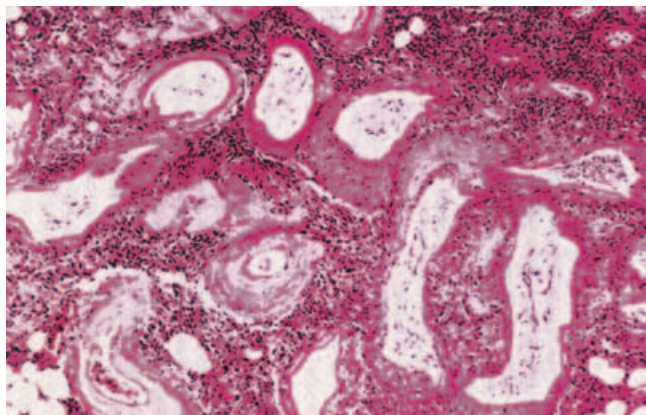
degeneration of lung tissue, impaired gas exchange, respiratory failure, and death. Progressive symptomatic lung disease may occur in patients diagnosed with sporadic LAM and such progression likewise would be predicted to occur in women with TSC-associated LAM. There is recent evidence that LAM may be caused by metastases of angiomyolipoma cells to the lung [34, 35]. These cells express estrogen receptors [36], and this finding has been used to help explain the gender bias in sporadic LAM as well as a rationale for a therapeutic trial of progesterone [37].

## CLASSIFICATION OF RENAL ANGIOMYOLIPOMATA

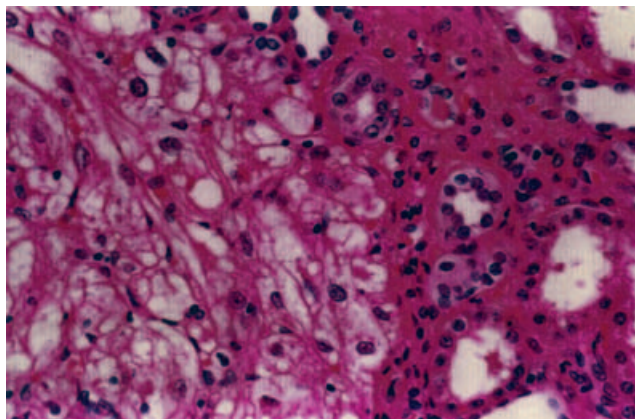
Angiomyolipomata were originally thought by Fischer [38] to be an abnormal proliferation of the tissues that are normally present in the kidney, and hence, he classified them as hamartomata. Dickinson et al [18] noted that fat and smooth muscle are not normally found in the renal parenchyma, and classified angiomyolipomata as choristomata. As basic science investigation has better defined these lesions, angiomyolipomata are best classified as neoplasia. This classification is supported by the finding that these lesions arise from clonal expansion based on nonrandom X chromosome inactivation [39] and exhibit lymph node invasion [40, 41]. The perivascular epithelioid cell has been implicated as the progenitor for a family of neoplasms, including angiomyolipoma, lymphangiomyoma, and clear cell tumors of the lung and pancreas [42, 43]. These cells have been proposed to differentiate into spindle-shaped cells with features of adipose, smooth muscle, and eosinophilic and clear epithelioid cells. A feature of these perivascular epithelioid cell-derived lesions is HMB-45 immunoreactivity; the spindle and epithelioid cells often stain with anti-smooth muscle actin while the fat cells stain with S-100 antibodies. While most often described in the kidneys, angiomyolipomata also have been identified in the liver [44], ovary [45], fallopian tube [46], spermatic cord [47], palate [48], and colon [49].

There are two basic types of angiomyolipoma. The classic form contains vascular, smooth muscle, and adipose tissue (Fig. 6). The contribution of each of these components can vary from lesion to lesion in the same kidney. The vascular component may be scant or may dominate the lesion [50]. Five different types of vessels within angiomyolipomata have recently been recognized [51], some of which are deficient in elastic fibers [52]. The smooth muscle component can be limited to a small amount cuffing the vasculature [53], or may be so extensive that imaging detects a solid mass devoid of fat [54]. In classic angiomyolipomata, there can be patches of smooth muscle cells that exhibit nuclear atypia with mitotic figures; despite these findings, such lesions typically do not behave as a malignant lesion. There are only a few case reports of sarcoma arising from an angiomyolipoma, which has been termed malignant angiomyolipoma [55, 56]. Like the smooth muscle and vascular component, the adipose element of angiomyolipomata can be variable. Most often the fat component is made up of mature fat tissue. Very rarely, renal angiomyolipomata can infiltrate surrounding tissue [57].

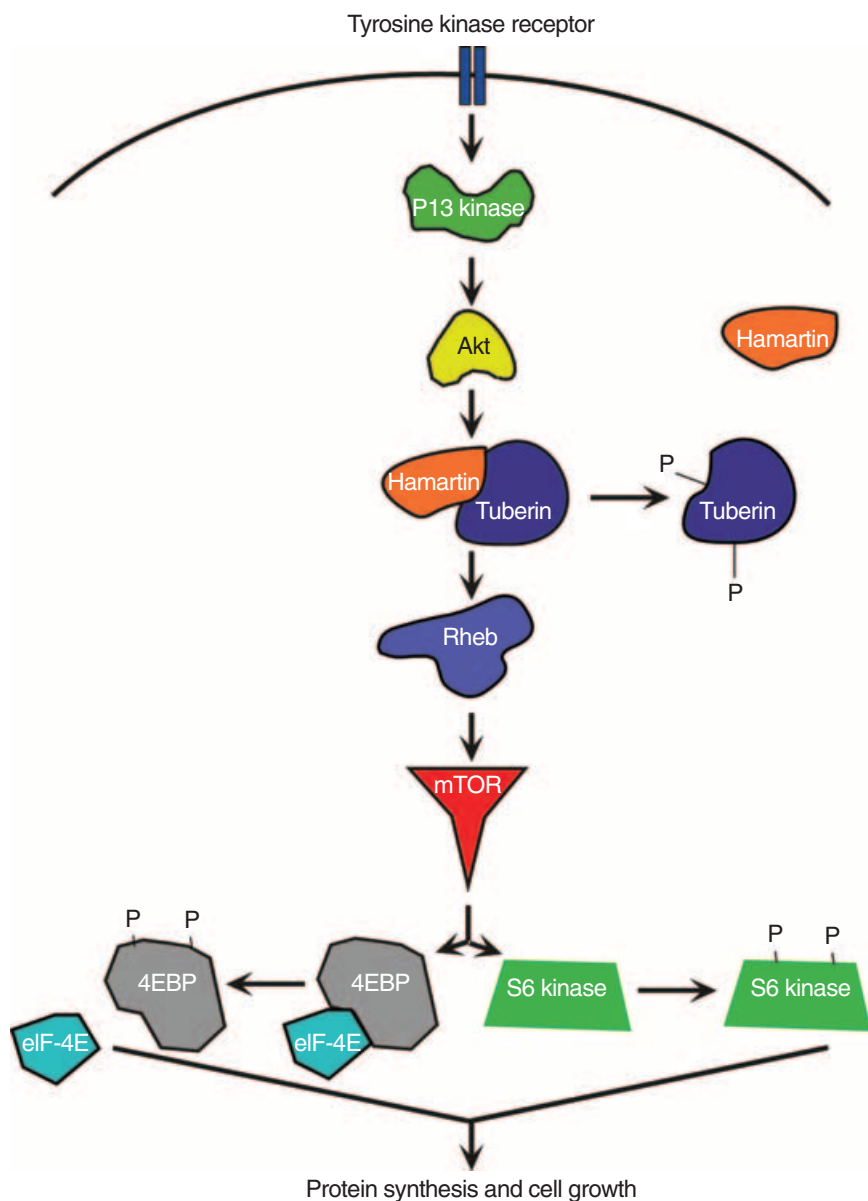
The epithelioid variant of angiomyolipomata has recently been described [58, 59]. These lesions have a large component of epithelioid cells (Fig. 7). The epithelioid cells may be polygonal with a slight degree of nuclear atypia, or atypical and variable in size; these lesions may



**Fig. 6. Classic renal angiomyolipoma histology using hematoxylin and eosin stain.** Note the multiple thick-walled blood vessels, smooth muscle cells, and fat cells.



**Fig. 7. Epithelioid renal angiomyolipoma histology using hematoxylin and eosin stain.** Note clear demarcation of normal renal tissue and the polygonal epithelioid cells.



**Fig. 8. Model for how tuberin and hamartin regulate cell growth.** Binding of ligands (such as insulin) to cell surface tyrosine kinase receptors results in autophosphorylation of the receptor, and docking of adaptor proteins and phosphatidylinositol 3'-kinase (PI3K). Protein kinase B (PKB), also known as Akt, is phosphorylated and activated, which in turn phosphorylates tuberin. Tuberin dissociates from hamartin, permitting phosphorylation and activation of mammalian target of rapamycin, or mTOR, by way of Rheb. Activated mTOR phosphorylates S6K and initiation factor 4E binding protein (4E-BP), and the kinase activity and release of the kinase activity and release of translation initiation factor eIF-4E promote protein synthesis and cell growth. Absence of tuberin permits constitutive activation of S6K and 4E-BP, which provides a persistent and inappropriate stimulus for growth (adapted in part from McManus and Alessi [113]).

exhibit significant mitotic activity. There are few or no abnormal vessels or fat cells in these lesions. Very aggressive epithelioid angiomyolipomata have been reported, sometimes as HMB-45 antibody–positive malignant angiomyolipomata, and these lesions can recur after resection and can be fatal [59–61]. Based on further analysis of these cases as well as other studies, Eble [62] postulates that the epithelioid renal angiomyolipomata are more aggressive than the more typical angiomyolipoma.

## ASSOCIATION WITH CANCER

Other neoplasms appear to be associated with angiomyolipomata. These include oncocytomas and renal cell carcinomas. Oncocytoma, a benign, renal epithelial cell neoplasm, consists of polygonal cells with abundant, finely granular cytoplasm filled with mitochondria. These lesions make up about 5% of surgically resected renal neoplasms [63], and may be more common in TSC [64]. The lesions histochemically label with epithelial cell markers but fail to express vimentin and are HMB-45 nonreactive [63, 65]. Another lesion, which histologically appears to be an oncocytoma, but lacking epithelial cell markers and is HMB-45–positive, has been described as an oncocytoma-like angiomyolipoma [63].

The concurrence of renal cell carcinoma and angiomyolipoma appears to be rare. Jimenez et al [64] identified only 52 cases in the literature, and was the uncertain whether patients with TSC were at increased risk for a renal cell neoplasm compared to the general population. Pea et al [66] note that the epithelioid variant of angiomyolipoma closely simulates renal cell carcinoma, making it difficult to determine the real frequency of authentic renal cell carcinomas among the reported cases in the literature. The epithelioid variety can also exhibit a clear cell histologic appearance [67]. A distinction between renal cell carcinoma and angiomyolipomata has been made in part based on the immunohistochemical findings. Renal cell carcinoma exhibit keratin but lack HMB-45 staining, while the epithelioid variety will demonstrate the reverse [66]. Tello et al [68] have performed a meta-analysis and failed to find a statistical relationship between TSC and renal cell carcinoma. However, the occurrence of renal cell carcinoma in children and young adults with TSC [69], including several reports of multifocal renal cell carcinoma in children with TSC under the age of 10 years, would indicate that an association does exist.

Two interesting observations may offer insight into the link between cancer and angiomyolipomata. First is that renal carcinoma in TSC has been seen in association with renal cystic disease [69], analogous to carcinoma associated with other (non-TSC) renal cystic diseases [70]. Perhaps the carcinoma risk is linked to the renal cystic disease and not to the angiomyolipomata. The second observation is that angiomyolipoma have been

noted to have other chromosomal abnormalities, suggesting the possibility that, in some lesions, the specific secondary chromosomal rearrangement may contribute to malignant progression [69]. Although the relationship of tuberous sclerosis and renal cell carcinoma is uncertain, angiomyolipoma can act aggressively, and can rarely undergo malignant transformation. Therefore, angiomyolipoma should be closely monitored to avoid undue patient risk [71].

## GENETICS OF ANGIOMYOLIPOMATA

Angiomyolipomata develop from clonal expansion of a cell that has acquired proliferative autonomy [39, 72, 73]. Genetic linkage analyses of families with TSC have led to the discovery of two genes that are associated with angiomyolipomata. These genes are *TSC1*, found at chromosome 9q34, and *TSC2* found at 16p13 [74]. Analysis of sporadic angiomyolipomata has likewise revealed an association with *TSC2* [75]. In a study of 130 sporadic (i.e., nonfamilial) TSC cases, 68% had germline *TSC2* mutations, 22% had no identifiable mutation, and 10% had germline *TSC1* mutations [76, 77].

Angiomyolipomata, TSC, and LAM related as well as at least some unrelated lesions, appear to be the consequence of somatic mutagenesis. The molecular pathogenesis of an angiomyolipoma associated with TSC involves the inheritance of a mutant allele compounded by a somatic mutation that results in a loss of heterozygosity (LOH). Patients with TSC have a germline mutation in the copy of the *TSC1* or *TSC2* gene that either arose sporadically or was inherited from the affected parent. Cells are heterozygous with one abnormal and one functional gene. The single normal allele is sufficient to ensure normal cell proliferation and organ development. However, sporadic somatic mutations of the wild-type allele in vulnerable tissues lead to a variable number of tumors. The cells of the lesion appear to be either homozygous or hemizygous for the mutant allele because they exhibit LOH at the involve TSC locus. The role of somatic mutagenesis in TSC has been clearly established [75, 78–80]. LOH of *TSC2* was also noted by Smolarek et al [81] in 7 of 13 angiomyolipomata from women with sporadic LAM, and specific *TSC2* mutations were identified [82]. In this sporadic form of disease, approximately half of the women also have renal angiomyolipomata. Angiomyolipomata not associated with sporadic LAM or TSC have also been reported to exhibit LOH at chromosome 16p13. Martignoni et al [83] studied epithelioid angiomyolipoma tissue from three patients without TSC or LAM, and found LOH at chromosome 16p13 in one of these patients. These findings raise the possibility that least some of the angiomyolipomata not associated with LAM or TSC also may be associated with mutations in the *TSC2* gene. These germline and somatic mutations

silence the locus and are an example of the two-hit hypothesis Knudson [84] proposed for retinoblastoma.

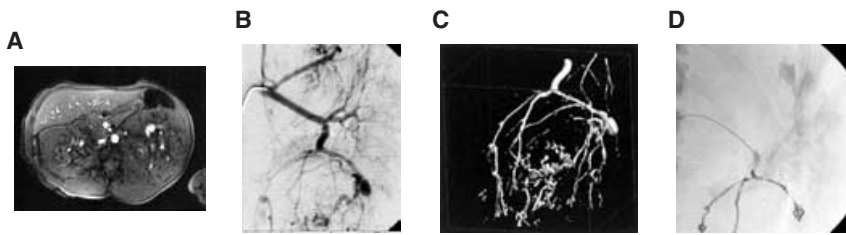
The origin of LAM cells is also controversial, but three lines of evidence suggest that angiomyolipoma smooth muscle cells metastasize to the lung, where they proliferate and progressively replace the normal lung tissue. First, TSC mutations in LAM cells and angiomyolipoma cells from sporadic LAM patients, who do not have germ line mutations in TSC genes, are identical, suggesting a common origin [82]. Second, TSC patients with LAM are more likely to have large or problematic angiomyolipomata, which are potentially more likely to seed the lung [28]. Studies from the University of Cincinnati and elsewhere have revealed that pulmonary cystic changes consistent with LAM are present in up to 40% of women with TSC [28–30]. Third, a recent genetic analysis of recurrent LAM lesions in a lung allograft after lung transplantation proved the recipient origin of smooth muscle cells in the lesion [34]. LAM cells isolated from the lung and angiomyolipomata cells share many genotypic and phenotypic characteristics, including genetic mutations in TSC genes and staining with specific markers, including the melanocyte-derived monoclonal antibody HMB-45 and to smooth muscle actin. Because of their biologic similarities and growing evidence that the lung lesion in TSC may arise from angiomyolipomata, we postulate that strategies that effectively control the growth of angiomyolipoma cells in the kidney may also control the growth of LAM cells in the lung. As explained above, an important feature of the cells in LAM and angiomyolipomata is that, in addition to an inherited mutation in one copy of their *TSC1* or *TSC2* genes, they have undergone a second somatic mutation that has disabled the wild-type gene. This second mutation produces a deficiency of either hamartin or tuberin, respectively. Insight into how this genetic difference between angiomyolipoma and normal cells leads to disease expression has only recently become available (for review, see [85]). Genetic analysis of *Drosophila* homologues *Tsc1* and *Tsc2* helped identify a role for hamartin and tuberin in cell organ morphology. Initially described by Farrus and Garcia-Bellido in 1976, the fruit fly *gigas* was found to have a mutation in the human homologue for *Tsc2* by Ito and Rubin [86]. Further work in this experimental system revealed that the *Tsc1* and *Tsc2* loci played a role in the regulation of cell and organ size. Homozygous inactivation of either *Tsc1* or *Tsc2* had identical phenotypic result, an increase in organ size that was due to an increase in cell size. Conversely, a simultaneous increase in the expression from both the *Tsc1* and *Tsc2* loci resulted in the opposite phenotype. Because cell size regulation had been associated with the PI3K-Akt-S6K pathway, genetic studies designed to elucidate the possible position of the *Tsc1* and *Tsc2* gene product in the pathway have been undertaken by several investigators.

Cultured mammalian cells lacking tuberin or hamartin constitutively produce a high level of S6K and 4EBP1 [87–89]. Treatment of these cells with rapamycin results in a rapid dephosphorylation and these treated cells become resistant to amino acid starvation [90]. These findings are consistent with the activation of the mammalian phosphatidylinositol 3'-kinase (PI3K)-Akt-S6K pathway and the pivotal role for mTOR in the absence of hamartin or tuberin (Fig. 8).

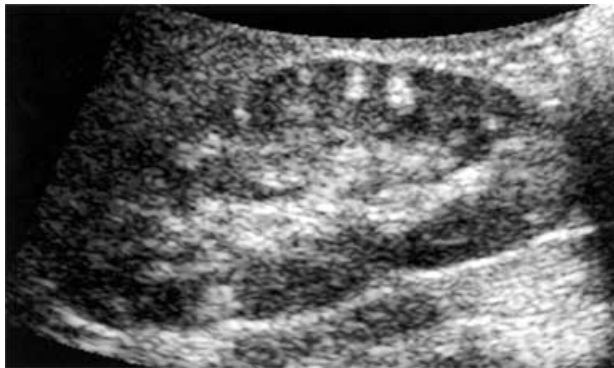
## CLINICAL MANAGEMENT

Angiomyolipomata are most often identified by imaging studies done to work up suspected disease, including hemorrhage, or as an incidental finding. Although these lesions can be quite large when identified, they typically are rather slow growing, and their large size attained over a longer time. Such predictable growth allows the clinician to identify a malignant lesion by a sudden increase in size, and underscores the value of periodic imaging. Large nonmalignant lesions can arise because of slow, continuous growth, or by the coalescence of multiple adjacent lesions. Lesions typically contain variable amounts of vascular, smooth muscle, and adipose elements. The composition is quite variable and they may also be composed of mostly solid elements such as smooth muscle. The epithelioid variety also contains very little or no fat nor the typical dysplastic vascular elements. The decision to biopsy such lesions is based on unusual growth and imaging characteristics. The risk of spontaneous hemorrhage, associated with aneurismal rupture [19] does not, by itself, increase the risk of bleeding following biopsy. The bleeding risk with biopsy is likely to be somewhat increased based on the dysplastic nature of the angiomyolipomata vasculature, but such is rarely the case in the epithelioid variety, and the vascular portion of the lesion can be crudely assessed by the degree of enhancement on imaging studies. In cases where the diagnosis is not clear, biopsy can guide therapy [91].

The primary reason to intervene in patients with renal angiomyolipomata has been to alleviate symptoms such as pain or hemorrhage, or to establish a diagnosis when the lesion has a low fat content that raises the suspicion of a carcinoma. Factors that affect the decision to intervene, as well as the method include the presence of symptoms, lesion size, visible aneurysms, renal reserve, pregnancy plans, patient occupation, activity, and compliance. The recent urological literature has embraced a renal sparing approach for angiomyolipomata [92]. Key to the long-term outcome of patients with multiple renal angiomyolipomata is the preservation of renal function. Current clinical measurements of renal function fail to measure renal reserve. This concept is critical because many case reports regarding nephron-sparing surgeries use normal serum creatinine values to indicate the



**Fig. 9. Renal aneurysm in an angiomyolipoma.** (A) Single proton gradient resonance (SPGR) sequence magnetic resonance imaging (MRI) revealing a 1.1 cm bright signal intensity in the lower pole of the left kidney compatible with a dilated or ectatic vessel or an aneurysm. (B) Angiography clearly showing the large aneurysm. (C) Three-dimensional reconstruction of vasculature to aid in embolization procedure. (D) Postembolization angiography showing the lack of blood flow to the vasculature, and the coils in place.



**Fig. 10. Renal ultrasound revealing multiple angiomyolipomata in a child.** Because these lesions typically contain a significant amount of adipose tissue, they are bright on ultrasound.

absence of renal damage [93, 94]. Because renal angiomyolipomata continue to grow, albeit slowly, indications for a total nephrectomy are limited and include a nonfunctioning kidney resulting in uncontrolled hypertension, local tissue invasion [95], tumor in the renal vein [96, 97], or very strong evidence of malignancy.

Partial or nephron-sparing nephrectomies run the risk of significant hemorrhage, and therefore should be undertaken only if unequivocally indicated. A suitable alternative to such invasive procedures is embolization (Fig. 9). Embolization, first used to treat angiomyolipomata approximately 20 years ago, obliterates the blood supply to the angiomyolipomata and thus reduces the risk of hemorrhage [98]. Embolization also has significant side effects. Following embolization, approximately 85% of patients develop post-embolization syndrome, including significant fever and pain [16, 98–109]. The use of glucocorticoids can ameliorate this complication [14]. Embolization is the preferred therapy and appears to be the most successful nephron-sparing procedure [92].

Although embolization and surgical therapies can successfully treat solitary lesions, the much more vexing clinical problem of coalescent renal angiomyolipomata that replace renal parenchyma has remained largely undressed (Fig. 10). When bleeding occurs in this circumstance, it can be impossible to identify which lesion is the source.

## ANIMAL MODELS OF ANGIOMYOLIPOMATA

Data from experimental animals and humans confirm the *in vivo* relevance of the Akt signaling pathways in tuberous sclerosis. Although not perfect mimics of the human disease, tuberin and hamartin heterozygous null mice develop several renal and hepatic neoplasms that are thought to be potential models for tuberous sclerosis [88, 110]. The hepatic tumors are rich in smooth muscle and are HMB-45–positive, consistent with the histological and immunohistochemical characteristics of LAM and angiomyolipoma lesions from patients. Female mice die from fatal hemorrhage into the liver lesion after 1 year of age, suggesting an influence of estrogen that also mimics human LAM. Most encouraging is that S6K is constitutively activated in the lesions of the TSC1+/- mice, and rapamycin quenches both the S6K phosphorylation and inappropriate cell growth in murine embryonic fibroblasts isolated from the animals [88]. Several investigators have demonstrated that rapamycin causes shrinkage of renal tumors in mouse [111] and rat [112] TSC models. The shrinkage was associated with inhibition of S6K phosphorylation and abundant apoptosis. S6K is constitutively active in LAM lesions, angiomyolipomata [51], and LAM cell models derived from humans and the Eker rat, and rapamycin can suppress inappropriate cell growth and S6K activation [87].

## CONCLUSIONS AND FUTURE DIRECTIONS

Renal angiomyolipomata are far from uncommon, and a great deal of progress has been made in understanding the genetics and biochemistry of this lesion, especially as it pertains to diseases like TSC and LAM. The optimum treatment of angiomyolipomata continues to be focused on sparing renal tissue. Initial published preclinical experimentation as well as ongoing work support the possibility that pharmacologic therapies may become available. Human trials to evaluate the utility of rapamycin in the treatment of renal angiomyolipoma associated with TSC and LAM are already underway. Should such therapies have efficacy, the discipline of nephrology that already has experience with drugs like rapamycin will likely play a dominant role in the care of these patients.

## ACKNOWLEDGMENTS

The authors would like to thank Elizabeth Henske, Frank McCormack, David N. Franz, and Clarke D. West for their careful manuscript review and constructive comments. The authors would also like to thank Elizabeth Henske for Figures 7 and 8. This work was supported by the following grants to J.J.B. from NIH (DK61458 and CA103486), LAM Foundation, TSAliance, PKD Foundation, and Kidney Foundation of Greater Cincinnati.

Reprint requests to John J. Bissler, M.D., Children's Hospital Research Foundation #5, ML#7022, 3333 Burnet Ave., Cincinnati, OH 45229-3039.

E-mail: john.bissler@cchmc.org

## REFERENCES

- UNITED STATES DEPARTMENT OF CENSUS: Population Clock, 2003
- FUJII Y, AJIMA J, OKA K, *et al*: Benign renal tumors detected among healthy adults by abdominal ultrasonography. *Eur Urol* 27:124-127, 1995
- GRAWITZ P: Demonstration eines grossen Angio-Myo-Lipoms der Niere. *Dtsch Med Wochenschr* 26:290, 1900
- HAJDU SI, FOOTE FW, JR.: Angiomyolipoma of the kidney: Report of 27 cases and review of the literature. *J Urol* 102:396-401, 1969
- HENSKE EP, AO X, SHORT MP, *et al*: Frequent progesterone receptor immunoreactivity in tuberous sclerosis-associated renal angiomyolipomas. *Mod Pathol* 11:665-668, 1998
- BOURNEVILLE DM: Sclerose tubereuse des ciconvolutions cerebrales; Idiotie et epilepsie hemiplegique. *Arch Neurol (Paris)* 1:81-91, 1880
- BOURNEVILLE DM, BRISSAUD E: A l'idiotie et epilepsie symptomatique de sclerose tubereuse ou hypertrophique. *Arch Neurol (Paris)* 10:29-39, 1900
- EWALT DH, SHEFFIELD E, SPARAGANA SP, *et al*: Renal lesion growth in children with tuberous sclerosis complex. *J Urol* 160:141-145, 1998
- LEMAITRE L, ROBERT Y, DUBRULLE F, *et al*: Renal angiomyolipoma: growth followed up with CT and/or US [see comments]. *Radiology* 197:598-602, 1995
- STEINER MS, GOLDMAN SM, FISHMAN EK, *et al*: The natural history of renal angiomyolipoma. *J Urol* 150:1782-1786, 1993
- BERNSTEIN J, ROBBINS TO: Renal involvement in tuberous sclerosis. *Ann New York Acad Sci* 615:36-49, 1991
- CHESA PONCE N, ARTILES HERNANDEZ JL, PONCE SOCORRO JM, *et al*: Wunderlich's syndrome as the first manifestation of a renal angiomyolipoma. *Arch Esp Urol* 48:305-308, 1995
- ADLER J, GREWELDINGER J, LITZKY G: "Macro" aneurysm in renal angiomyolipoma: Two cases, with therapeutic embolization in one patient. *Urol Radiol* 6:201-203, 1984
- BISSLER JJ, RACADIO J, DONNELLY LF, *et al*: Reduction of postembolization syndrome after ablation of renal angiomyolipoma. *Am J Kidney Dis* 39:966-971, 2002
- PODE D, MERETIK S, SHAPIRO A, *et al*: Diagnosis and management of renal angiomyolipoma. *Urol* 25:461-467, 1985
- KESSLER OJ, GILLON G, NEUMAN M, *et al*: Management of renal angiomyolipoma: Analysis of 15 cases. *Eur Urol* 33:572-575, 1998
- WEBB DW, KABALA J, OSBORNE JP: A population study of renal disease in patients with tuberous sclerosis. *Br J Urol* 74:151-154, 1994
- DICKINSON M, RUCKLE H, BEAGHLER M, *et al*: Renal angiomyolipoma: Optimal treatment based on size and symptoms. *Clin Nephrol* 49:281-286, 1998
- YAMAKADO K, TANAKA N, NAKAGAWA T, *et al*: Renal angiomyolipoma: Relationships between tumor size, aneurysm formation, and rupture. *Radiology* 225:78-82, 2002
- SCHILLINGER F, MONTAGNAC R: Chronic renal failure and its treatment in tuberous sclerosis. *Nephrol Dial Transplant* 11:481-485, 1996
- CLARKE A, HANCOCK E, KINGSWOOD C, *et al*: End-stage renal failure in adults with the tuberous sclerosis complex. *Nephrol Dial Transplant* 14:988-991, 1999
- SHEPHERD CW, GOMEZ MR, LIE JT, *et al*: Causes of death in patients with tuberous sclerosis. *Mayo Clin Proc* 66:792-796, 1991
- COOK JA, OLIVER K, MUELLER RF, *et al*: A cross sectional study of renal involvement in tuberous sclerosis. *J Med Genet* 33:480-484, 1996
- BROOK-CARTER PT, PERAL B, WARD CJ, *et al*: Deletion of the TSC2 and PKD1 genes associated with severe infantile polycystic kidney disease—a contiguous gene syndrome. *Nat Genet* 8:328-332, 1994
- SAMPSON JR, MAHESHWAR MM, ASPINWALL R, *et al*: Renal cystic disease in tuberous sclerosis: Role of the polycystic kidney disease 1 gene. *Am J Hum Genet* 61:843-851, 1997
- TAYLOR JR, RYU J, COLBY TV, *et al*: Lymphangioleiomyomatosis. Clinical course in 32 patients. *N Engl J Med* 323:1254-1260, 1990
- AUBRY MC, MYERS JL, RYU JH, *et al*: Pulmonary lymphangioleiomyomatosis in a man. *Am J Respir Crit Care Med* 162:749-752, 2000
- FRANZ DN, BRODY A, MEYER C, *et al*: Mutational and radiographic analysis of pulmonary disease consistent with lymphangioleiomyomatosis and micronodular pneumocyte hyperplasia in women with tuberous sclerosis. *Am J Respir Crit Care Med* 164:661-668, 2001
- MOSS J, AVILA NA, BARNES PM, *et al*: Prevalence and clinical characteristics of lymphangioleiomyomatosis (LAM) in patients with tuberous sclerosis complex. *Am J Respir Crit Care Med* 164:669-671, 2001
- COSTELLO LC, HARTMAN TE, RYU JH: High frequency of pulmonary lymphangioleiomyomatosis in women with tuberous sclerosis complex. *Mayo Clin Proc* 75:591-594, 2000
- HANCOCK E, TOMKINS S, SAMPSON J, *et al*: Lymphangioleiomyomatosis and tuberous sclerosis. *Respir Med* 96:7-13, 2002
- BYRNES S: *Lymphangioleiomyomatosis Registry*, Cincinnati, LAM Foundation, 2003
- CHAN JK, TSANG WY, PAU MY, *et al*: Lymphangioleiomyomatosis and angiomyolipoma: Closely related entities characterized by hamartomatous proliferation of HMB-45-positive smooth muscle. *Histopathology* 22:445-455, 1993
- KARBOWNICZEK M, ASTRINDIS A, BALSARA BR, *et al*: Recurrent lymphangioleiomyomatosis after transplantation: Genetic analyses reveal a metastatic mechanism. *Am J Respir Crit Care Med* 31:31, 2002
- MARUYAMA H, SEYAMA K, SOBAJIMA J, *et al*: Multifocal micronodular pneumocyte hyperplasia and lymphangioleiomyomatosis in tuberous sclerosis with a TSC2 gene. *Mod Pathol* 14:609-614, 2001
- LOGGINIDOU H, AO X, RUSSO I, *et al*: Frequent estrogen and progesterone receptor immunoreactivity in renal angiomyolipomas from women with pulmonary lymphangioleiomyomatosis. *Chest* 117:25-30, 2000
- MATSUI K, TAKEDA K, YU ZX, *et al*: Downregulation of estrogen and progesterone receptors in the abnormal smooth muscle cells in pulmonary lymphangioleiomyomatosis following therapy. An immunohistochemical study. *Am J Respir Crit Care Med* 161:1002-1009, 2000
- FISCHER W: Die niereutemoren bi der tuberösen hirscklerose. *Beitr z path Anat u z allg Path* 1:235, 1911
- GREEN AJ, SEPP T, YATES JR: Clonality of tuberous sclerosis hamartomas shown by non-random X-chromosome inactivation. *Hum Genet* 97:240-243, 1996
- EBLE JN: Angiomyolipoma of kidney. *Semin Diagn Pathol* 15:21-40, 1998
- BRECHER ME, GILL WB, STRAUS FH: Angiomyolipoma with regional lymph node involvement and long-term follow-up study. *Hum Pathol* 17:962-963, 1986
- BONETTI F, PEA M, MARTIGNONI G, *et al*: Clear cell ("sugar") tumor of the lung is a lesion strictly related to angiomyolipoma—The concept of a family of lesions characterized by the presence of the perivascular epithelioid cells (PEC). *Pathology* 26:230-236, 1994
- ZAMBONI G, PEA M, MARTIGNONI G, *et al*: Clear cell "sugar" tumor of the pancreas. A novel member of the family of lesions characterized by the presence of perivascular epithelioid cells. *Am J Surg Pathol* 20:722-730, 1996
- JOZWIAK S, MICHALOWICZ R, PEDICH M, *et al*: Hepatic hamartoma in tuberous sclerosis. *Lancet* 339:180, 1992
- ANDERSON AE, YANG X, YOUNG RH: Epithelioid angiomyolipoma of the ovary: A case report and literature review. *Int J Gynecol Pathol* 21:69-73, 2002

46. KATZ DA, THOM D, BOGARD P, *et al*: Angiomyolipoma of the fallopian tube. *Am J Obstet Gynecol* 148:341–343, 1984
47. CASTILLENTE TA, BERTIN AP: Angiomyolipoma of the spermatic cord: Case report and literature review. *J Urol* 142:1308–1309, 1989
48. GUTMANN J, CIFUENTES C, VICUNA R, *et al*: Intraoral angiomyolipoma. *Oral Surg Oral Med Oral Pathol* 39:945–948, 1975
49. HIKASA Y, NARABAYASHI T, YAMAMURA M, *et al*: Angiomyolipoma of the colon: A new entity in colonic polypoid lesions. *Gastroenterol Jpn* 24:407–409, 1989
50. LIN CN, CHIANG HS, HSU SI, *et al*: Renal angiomyolipoma with a prominent angiomatous component and extramedullary hematopoiesis: A case report. *Chin Med J* 53:185–187, 1994
51. KARBOWNICZEK M, YU J, HENSKE EP: Renal angiomyolipomas from patients with sporadic lymphangiomyomatosis contain both neoplastic and non-neoplastic vascular structures. *Am J Pathol* 162:491–500, 2003
52. TWEEDDALE DN, DAWE CJ, McDONALD JR: Angiolipoleiomyoma of the kidney: report of a case with observations on histogenesis. *Cancer* 8:764–770, 1955
53. WONG AL, McGEORGE A, CLARK AH: Renal angiomyolipoma: A review of the literature and a report of 4 cases. *Brit J Urol* 53:406–411, 1981
54. OBUZ F, KARABAY N, SECIL M, *et al*: Various radiological appearances of angiomyolipomas in the same kidney. *Eur Radiol* 10:897–899, 2000
55. FERRY JA, MALT RA, YOUNG RH: Renal angiomyolipoma with sarcomatous transformation and pulmonary metastases. *Am J Surg Pathol* 15:1083–1088, 1991
56. LOWE BA, BREWER J, HOUGHTON DC, *et al*: Malignant transformation of angiomyolipoma. *J Urol* 147:1356–1358, 1992
57. FARROW GM, HARRISON EG, JR, UTZ DC, *et al*: Renal angiomyolipoma. A clinicopathologic study of 32 cases. *Cancer* 22:564–570, 1968
58. MAI KT, PERKINS DG, COLLINS JP: Epithelioid cell variant of renal angiomyolipoma [see comments]. *Histopathology* 28:277–280, 1996
59. EBLE JN, AMIN MB, YOUNG RH: Epithelioid angiomyolipoma of the kidney: A report of five cases with a prominent and diagnostically confusing epithelioid smooth muscle component. *Am J Surg Pathol* 21:1123–1130, 1997
60. BJORNSSON J, SHORT MP, KWIATKOWSKI DJ, *et al*: Tuberous sclerosis-associated renal cell carcinoma. Clinical, pathological, and genetic features. *Am J Pathol* 149:1201–1208, 1996
61. HARDMAN JA, McNICHOLAS TA, KIRKHAM N, *et al*: Recurrent renal angiomyolipoma associated with renal carcinoma in a patient with tuberous sclerosis. *Brit J Urol* 72:983–984, 1993
62. EBLE JN: Angiomyolipoma of kidney. *Semin Diag Pathol* 15:21–40, 1998
63. MARTIGNONI G, PEA M, BONETTI F, *et al*: Oncocytoma-like angiomyolipoma. A clinicopathologic and immunohistochemical study of 2 cases. *Arch Pathol Lab Med* 126:610–612, 2002
64. JIMENEZ RE, EBLE JN, REUTER VE, *et al*: Concurrent angiomyolipoma and renal cell neoplasia: A study of 36 cases. *Mod Pathol* 14:157–163, 2001
65. PITZ S, MOLL R, STORKEL S, *et al*: Expression of intermediate filament proteins in subtypes of renal cell carcinomas and in renal oncocytomas. Distinction of two classes of renal cell tumors. *Lab Invest* 56:642–653, 1987
66. PEA M, BONETTI F, MARTIGNONI G, *et al*: Apparent renal cell carcinomas in tuberous sclerosis are heterogeneous: The identification of malignant epithelioid angiomyolipoma [see comments]. *Am J Surg Pathol* 22:180–187, 1998
67. SAITO K, FUJII Y, KASAHARA I, *et al*: Malignant clear cell “sugar” tumor of the kidney: Clear cell variant of epithelioid angiomyolipoma. *J Urol* 168:2533–2534, 2002
68. TELLO R, BLICKMAN JG, BUONOMO C, *et al*: Meta analysis of the relationship between tuberous sclerosis complex and renal cell carcinoma. *Eur J Radiol* 27:131–138, 1998
69. AL-SALEEM T, WESSNER LL, SCHEITHAUER BW, *et al*: Malignant tumors of the kidney, brain, and soft tissues in children and young adults with the tuberous sclerosis complex. *Cancer* 83:2208–2216, 1998
70. ANDERSON GA, DEGROOT D, LAWSON RK: Polycystic renal disease. *Urology* 42:358–364, 1993
71. MARTIGNONI G, PEA M, RIGAUD G, *et al*: Renal angiomyolipoma with epithelioid sarcomatous transformation and metastases: Demonstration of the same genetic defects in the primary and metastatic lesions. *Am J Surg Pathol* 24:889–894, 2000
72. PARADIS V, LAURENDEAU I, VIEILLEFOND A, *et al*: Clonal analysis of renal sporadic angiomyolipomas. *Hum Pathol* 29:1063–1067, 1998
73. SAXENA A, ALPORT EC, CUSTEAD S, *et al*: Molecular analysis of clonality of sporadic angiomyolipoma. *J Pathol* 189:79–84, 1999
74. POVEY S, ATTWOOD J, CHADWICK B, *et al*: Report on the Fifth International Workshop on Chromosome 9 held at Eynsham, Oxfordshire, UK, September 4–6, 1996. *Ann Hum Genet* 61:183–206, 1997
75. HENSKE EP, NEUMANN HP, SCHEITHAUER BW, *et al*: Loss of heterozygosity in the tuberous sclerosis (TSC2) region of chromosome band 16p13 occurs in sporadic as well as TSC-associated renal angiomyolipomas. *Genes Chrom Cancer* 13:295–298, 1995
76. JONES AC, SHYAMSUNDAR MM, THOMAS MW, *et al*: Comprehensive mutation analysis of TSC1 and TSC2 and phenotypic correlations in 150 families with tuberous sclerosis. *Am J Hum Genet* 64:1305–1315, 1999
77. DABORA SL, JOZWIAK S, FRANZ DN, *et al*: Mutational analysis in a cohort of 224 tuberous sclerosis patients indicates increased severity of TSC2, compared with TSC1, disease in multiple organs. *Am J Hum Genet* 68:64–80, 2001
78. NIIDA Y, STEMMER-RACHAMIMOV AO, LOGRIP M, *et al*: Survey of somatic mutations in tuberous sclerosis complex (TSC) hamartomas suggests different genetic mechanisms for pathogenesis of TSC lesions. *Am J Hum Genet* 69:493–503, 2001
79. HENSKE EP, SCHEITHAUER BW, SHORT MP, *et al*: Allelic loss is frequent in tuberous sclerosis kidney lesions but rare in brain lesions. *Am J Hum Genet* 59:400–406, 1996
80. SEPP T, YATES JR, GREEN AJ: Loss of heterozygosity in tuberous sclerosis hamartomas. *J Med Genet* 33:962–964, 1996
81. SMOLAREK TA, WESSNER LL, McCORMACK FX, *et al*: Evidence that lymphangiomyomatosis is caused by TSC2 mutations: Chromosome 16p13 loss of heterozygosity in angiomyolipomas and lymph nodes from women with lymphangiomyomatosis. *Am J Hum Genet* 62:810–815, 1998
82. CARSILO T, ASTRINIDIS A, HENSKE EP: Mutations in the tuberous sclerosis complex gene TSC2 are a cause of sporadic pulmonary lymphangiomyomatosis. *Proc Natl Acad Sci USA* 97:6085–6090, 2000
83. MARTIGNONI G, PEA M, BONETTI F, *et al*: Carcinomalike monotypic epithelioid angiomyolipoma in patients without evidence of tuberous sclerosis: A clinicopathologic and genetic study. *Am J Surg Pathol* 22:663–672, 1998
84. KNUDSON AG, JR.: Mutation and cancer: Statistical study of retinoblastoma. *Proc Natl Acad Sci USA* 68:820–823, 1971
85. KWIATKOWSKI DJ: Tuberous sclerosis: From tubers to mTOR. *Ann Hum Genet* 67:87–96, 2003
86. ITO N, RUBIN GM: Gigas, a Drosophila homolog of tuberous sclerosis gene product-2, regulates the cell cycle. *Cell* 96:529–539, 1999
87. GONCHAROVA EA, GONCHAROV DA, ESZTERHAS A, *et al*: Tuberin regulates p70 S6 kinase activation and ribosomal protein S6 phosphorylation. A role for the TSC2 tumor suppressor gene in pulmonary lymphangiomyomatosis (LAM). *J Biol Chem* 277:30958–30967, 2002
88. KWIATKOWSKI DJ, ZHANG H, BANDURA JL, *et al*: A mouse model of TSC1 reveals sex-dependent lethality from liver hemangiomas, and up-regulation of p70S6 kinase activity in Tsc1 null cells. *Hum Mol Genet* 11:525–534, 2002
89. ONDA H, CRINO PB, ZHANG H, *et al*: Tsc2 null murine neuroepithelial cells are a model for human tuber giant cells, and show activation of an mTOR pathway. *Mol Cell Neurosci* 21:561–574, 2002
90. GAO X, ZHANG Y, ARRAZOLA P, *et al*: Tsc tumour suppressor proteins antagonize amino-acid-TOR signalling. *Nat Cell Biol* 4:699–704, 2002
91. RYBICKI FJ, SHU KM, CIBAS ES, *et al*: Percutaneous biopsy of renal masses: Sensitivity and negative predictive value stratified by clinical setting and size of masses. *AJR Am J Roentgenol* 180:1281–1287, 2003

92. NELSON CP, SANDA MG: Contemporary diagnosis and management of renal angiomyolipoma. *J Urol* 168:1315–1325, 2002
93. FAZELI-MATIN S, NOVICK AC: Nephron-sparing surgery for renal angiomyolipoma. *Urology* 52:577–583, 1998
94. SHIROYANAGI Y, KONDO T, TOMITA E, *et al*: Nephron-sparing tumorectomy for a large benign renal mass: A case of massive bilateral renal angiomyolipomas associated with tuberous sclerosis. *Int J Urol* 9:117–119, 2002
95. KRAGEL PJ, TOKER C: Infiltrating recurrent renal angiomyolipoma with fatal outcome. *J Urol* 133:90–91, 1985
96. ARENSON AM, GRAHAM RT, SHAW P, *et al*: Angiomyolipoma of the kidney extending into the inferior vena cava: Sonographic and CT findings. *AJR Am J Roentgenol* 151:1159–1161, 1988
97. BACK W, HEINE M, POTEMPA D: Intravaskuläre Form eines Angiomyolipoms der Niere. Fallbericht und Literaturübersicht. *Pathologe* 13:212–214, 1992
98. MOORHEAD JD, FRITZSCHE P, HADLEY HL: Management of hemorrhage secondary to renal angiomyolipoma with selective arterial embolization. *J Urol* 117:122–123, 1977
99. YANAI H, SASAGAWA I, KUBOTA Y, *et al*: Spontaneous hemorrhage during pregnancy secondary to renal angiomyolipoma. *Urol Int* 56:188–191, 1996
100. EDELMAN MA, MITTY HA, DAN SJ, *et al*: Angiomyolipoma: Postembolization liquefaction and percutaneous drainage. *Urol Radiol* 12:145–147, 1990
101. SANCHEZ FW, VUJIC I, AYRES RI, *et al*: Hemorrhagic renal angiomyolipoma: Superselective renal arterial embolization for preservation of renal function. *Cardiovasc Intervent Radiol* 8:39–42, 1985
102. VAN BAAL JG, LIPS P, LUTH W, *et al*: Percutaneous transcatheter embolization of symptomatic renal angiomyolipomas: A report of four cases. *Netherlands J Surg* 42:72–77, 1990
103. KENNELLY MJ, GROSSMAN HB, CHO KJ: Outcome analysis of 42 cases of renal angiomyolipoma [see comments]. *J Urol* 152:1988–1991, 1994
104. SOULEN MC, FAYKUS MH, JR., SHLANSKY-GOLDBERG RD, *et al*: Elective embolization for prevention of hemorrhage from renal angiomyolipomas. *J Vasc Intervent Radiol* 5:587–591, 1994
105. HAMLIN JA, SMITH DC, TAYLOR FC, *et al*: Renal angiomyolipomas: Long-term follow-up of embolization for acute hemorrhage. *Can Assoc Radiol J* 48:191–198, 1997
106. MOURIKIS D, CHATZIOANNOU A, ANTONIOU A, *et al*: Selective arterial embolization in the management of symptomatic renal angiomyolipomas. *Eur J Radiol* 32:153–159, 1999
107. LEE W, KIM TS, CHUNG JW, *et al*: Renal angiomyolipoma: Embolotherapy with a mixture of alcohol and iodized oil. *J Vasc Intervent Radiol* 9:255–261, 1998
108. UCHINO A, ITOH K, EGASHIRA K, *et al*: Therapeutic embolization for renal angiomyolipoma: Case report and review of the literature. *Radiat Med* 5:191–194, 1987
109. KEHAGIAS D, MOURIKIS D, KOUSARIS M, *et al*: Management of renal angiomyolipoma by selective arterial embolization. *Urol Int* 60:113–117, 1998
110. ONDA H, LUECK A, MARKS PW, *et al*: Tsc2(+/-) mice develop tumors in multiple sites that express gelsolin and are influenced by genetic background. *J Clin Invest* 104:687–695, 1999
111. EL-HASHEMITE N, WALKER V, ZHANG H, *et al*: Loss of Tsc1 or Tsc2 induces vascular endothelial growth factor production through mammalian target of rapamycin. *Cancer Res* 63:5173–5177, 2003
112. KENERSON HL, AICHER LD, TRUE LD, *et al*: Activated mammalian target of rapamycin pathway in the pathogenesis of tuberous sclerosis complex renal tumors. *Cancer Res* 62:5645–5650, 2002
113. MCMANUS EJ, ALESSI DR: TSC1-TSC2: A complex tale of PKB-mediated S6K regulation. *Nat Cell Biol* 4:E214–E216, 2002